

PennHIP Report

Referring Veterinarian: Dr Dagmar Schouten

Email: rpalmer@cedarwoodvet.ca

Clinic Name: Cedarwood Veterinary & Animal
Emergency HospitalClinic Address: 7644 Gaetz Ave
Red Deer, AB T4P 2A8

Phone:

Fax: (403) 346-9925

Patient Information

Client: Pearsall, Chad and Chantrelle

Patient Name: Wiley

Reg. Name: Shepherds Rest Wild, Wild West

PennHIP Num: 191835

Species: Canine

Date of Birth: 20 Jun 2021

Sex: Male

Date of Study: 26 Jul 2023

Date of Report: 27 Jul 2023

Tattoo Num:

Patient ID: 268098

Registration Num:

Microchip Num: 981020031251328

Breed: ANATOLIAN SHEPHERD

Age: 25 months

Weight: 156.5 lbs/71 kgs

Date Submitted: 27 Jul 2023

Findings

Distraction Index (DI): Right DI = 0.27, Left DI = 0.26.

Osteoarthritis (OA): **No radiographic evidence of OA for either hip.**

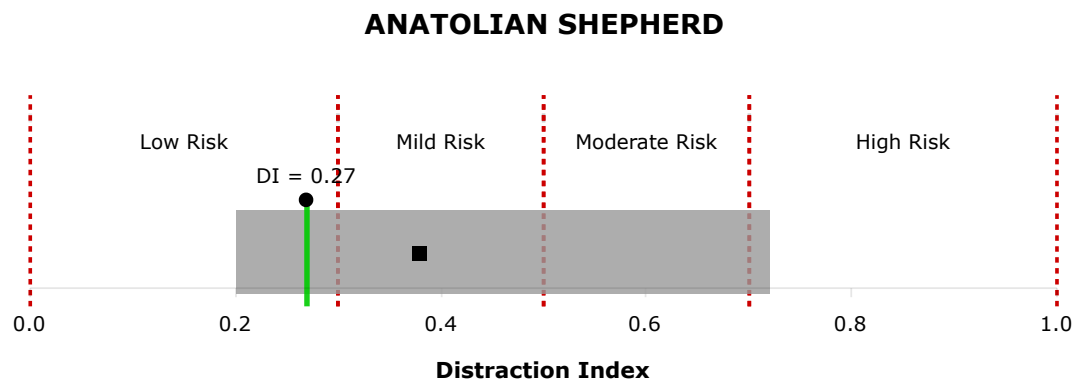
Cavitation/Other Findings: No cavitation present.

Interpretation

Distraction Index (DI): The laxity ranking is based on the hip with the greater laxity (larger DI). In this case the DI used is 0.27.

OA Risk Category: The DI is less than or equal to 0.30. This patient is at minimal risk for hip OA.

Distraction Index Chart:



BREED STATISTICS: This interpretation is based on a cross-section of 274 canine patients of the ANATOLIAN SHEPHERD breed in the AIS PennHIP database. The gray strip represents the central 90% range of DIs (0.20 - 0.72) for the breed. The breed average DI is 0.38 (solid square). The patient DI is the solid circle (0.27).

SUMMARY: The degree of laxity (DI = 0.27) falls within the central 90% range of DIs for the breed. This amount of hip laxity places hip at a minimal risk to develop hip OA. **No radiographic evidence of OA for either hip.**

